



**„For my patients
who need
eXtra care!“**

Dyract® XTRA
THE CARIES PREVENTING RESTORATIVE

Selected studies

For better dentistry

DENTSPLY

Introduction

The 1st generation of Dyract®, introduced in 1993, was developed in an attempt to combine the best properties of composites and glass-ionomers. Composites offer surface hardness, physical strength, low shrinkage and resistance to wear, while glass-ionomers (glass polyalkenoates) offer low technique sensitivity and release fluoride ions but have the disadvantage of being rather opaque and very brittle.

Dyract®eXtra is the 3rd generation of compomer restorative materials developed by DENTSPLY. Long-term fluoride release is characteristic for this product group. The clinical significance of this feature has been discussed controversially for a long time. Today with more than 250 full papers listed in PubMed on fluoride-releasing restoratives [Wiegand et al., 2007]¹ it can be concluded that both glass-ionomers and DENTSPLY compomers show cariostatic properties under simulated cariogenic conditions in vitro. In addition, a recent in-situ study undertaken by Lennon et al. [2007]² proves that Dyract®eXtra provides a caries-preventive effect on approximal surfaces.

The following pages contain summaries of the most important studies on the Dyract® brand.

¹ Wiegand A, Buchalla W, Attin T: Review on fluoride-releasing restorative materials – Fluoride release and uptake characteristics, antibacterial activity and influence on caries formation. *Dent Mater* 2007;23:3;343-362.

² Lennon AM, Wiegand A, Buchalla W, Attin T: Approximal caries development in surfaces in contact with fluoride-releasing and non-fluoride-releasing restorative materials: an in-situ study. *Eur J Oral Sci* 2007;115:497-501.

Contents:

European Archives of Pediatric Dentistry 2007;8:29-35

Restorative materials in the primary dentition of poli-caries patients

N. Krämer, U. Lohbauer, R. Frankenberger

..... 4

Deutsche Zahnärztliche Zeitschrift 2008;63:743-748

Quality of Class II compomer fillings after five years

C. Benz, R. Hickel

..... 9

European Journal of Oral Sciences 2007;115:497-501

Approximal caries development in surfaces in contact with fluoride-releasing and non-fluoride-releasing restorative materials: an in-situ study

A.M. Lennon, A. Wiegand, W. Buchalla, T. Attin

..... 13

Journal of Dentistry 2005;33:275-281

Restoration materials for primary molars – results from a European survey

V. Buerkle, J. Kuehnisch, M. Guelmann, R. Hickel

..... 17

Restorative materials in the primary dentition of poli-caries patients*

N. Krämer, U. Lohbauer**, R. Frankenberger***

** Dept Paediatric Dentistry, University Medical Centre Carl Gustav Carus, Dresden;*

*** Dental Clinic J: Operative Dentistry, Periodontology and Paediatric Dentistry, University Medical Centre, Erlangen; Germany.*

Acknowledgements:

This paper was given as a Keynote lecture at the 8th Congress of the European Academy of Paediatric Dentistry, Amsterdam, June 9th, 2006

Background

Despite an overall caries decline in children, still 50-60 % of carious primary teeth of 6-year-olds remain untreated, in 3-year-olds 13 %. There are an increasing number of poli-caries patients with insufficiently treated primary teeth. Therefore, early treatment is fundamental. Review: The assessment and indication for the use of restorative materials can be summarized as follows: Glass-ionomer cements (GIC) are associated with easy handling and high fluoride release. This makes them attractive especially for Class I cavities in uncooperative children. However, low flexural strength causes high fracture rates in Class II cavities. Further developments (viscous and resin-modified GIC) have improved handling characteristics, but conventional non-resin-modified GIC are still prone to fracture. Compomers exhibit a clear potential as an alternative to amalgam. Long-term results are good even in stress-bearing areas. The compliance of the child should at least last long enough for adhesive application. Resin composites are still the most time-consuming alternative. Under a correct application protocol, resin composites behave in a similar manner to com-

gomers. Therefore, the effort has to be judged individually. Finally, especially in severely decayed teeth and after endodontic treatment, preformed metal crowns should be taken into account as a last and appropriate alternative to direct restorations.

Restorative materials for primary teeth

Amalgam. This material has delivered acceptable results in primary teeth for over a century. Mean survival time per year was estimated to be around 3 years, mean reason for failure was secondary caries [Kilpatrick. 1993]¹; [Mjor et al., 2002]². Hickel et al. [2005]³ calculated an 8 % annual failure rate for amalgam in primary molars. During the last two decades, amalgam was considerably reduced due to inadequate pseudo-biological critique, but also due to aesthetic demands of parents.

Viscous Glass-ionomer Cements. Viscous GIC (VGIC) are packable and therefore of some interest [Burke et al., 2002]⁴. However, due to their low flexural strength and fatigue performance, being about the same as conventional GIC, the indication spectrum remains limited. Although filler sizes were considerably reduced compared with formerly, the ‘polishability’ is still poor. Our study with a metal-reinforced VGIC (Hi-Dense, Shofu) exactly matches preclinical findings in the laboratory [Krämer and Frankenberger, 2001]⁵. In vitro we found flexural properties and fatigue to be in the same in a range of older materials [Frankenberger et al., 1999a]⁶, and in vivo this was confirmed by a substantial fracture rate in Class II cavities. After two years of clinical service, more than 40 % of Class II restorations had failed. Clinical trials confirmed a success rate severely compromised by poor flexural strength characteristics [Ostlund et al., 1992]⁷; [Espelid et al., 1999]⁸; [Hubel and Majare, 2003]⁹. On the other hand, the fast and easy handling made it favourable for Class I defects and in uncooperative children.

Resin-modified GIC. Resin-modified GIC (RMGIC) is used for both anterior and posterior cavities [Qvist et al., 2004b]¹⁰. From the beginning it was thought to be advantageous to be achieving the polymerization process by visible light, however, small increments (< 3 mm) are mandatory [Burke et al., 1990]¹¹. But RMGIC contain large glass particles which lead to a visible surface roughness.

RMGIC have been investigated in several clinical trials [Espelid et al., 1999]⁸; [Qvist et al., 2004a]¹²; [Qvist et al., 2004b]¹⁰. Compared with VGIC, improved flexural strength seems to be responsible for increased success rates being characterized by less marginal and bulk fractures. Even compared with amalgam, RMGIC were more successful [Qvist et al., 2004b]¹⁰. The main advantages are high fluoride release and consequently less secondary caries, which was also confirmed histologically by Donlay et al. [1999]¹³ who reported an inhibition of enamel demineralization at restoration margins in vivo. Recent trends concerning the further development of RMGIC are focussing on smaller filler particles for improved polishability and aesthetics. The relatively high percentage of HEMA (hydroxy-ethyl methacrylate; 10-12 %wt.), however, will hardly be reduced. Further toxicological assessments have yet to clarify whether these restorations are biologically unsafe [Reichl et al., 2002]¹⁴.

Compomer

Compomers (polyacid-modified resin composites, COM) were introduced in 1994 for posterior and anterior restorations [Ernst et al., 1995]¹⁵; [Garcia-Godoy et al., 2000]¹⁶. Today more than 60 % of restorations in primary teeth are tooth-coloured [Tran and Messer, 2003]¹⁷. COMs are commonly used with one-step adhesives which apparently deliver dentine adhesions being sufficient to no longer use retentive preparations [Qvist et al., 2004a]¹². Roeters investigated Dyract® (DENTSPLY, Konstanz, Germany) in classes I and II in primary molars demonstrating long-term success [Roeters et al., 1998]¹⁸. Compared with GIC, improved flexural properties were verified in vivo by low fracture rates. After three years of clinical service, wear was also not a problem. According to the authors, an average compliance is sufficient for clinical success and

secondary caries does not play a major role. Prime&Bond® alone was used without any lining, and no hypersensitivities or pulpitis were found [Roeters et al., 1998]¹⁸. A split-mouth study with a COM (Compoglass®, Ivoclar Vivadent, Schaan, Liechtenstein) and a resin composite (TPH® Spectrum®, DENTSPLY) did not reveal differences between materials [Attin et al., 2001]¹⁹.

Conclusions

All restorative techniques exhibit strengths and weaknesses. An assessment of the materials can be summarized as follows:

- GICs are favourable for Class I cavities and in uncooperative children.
- Compomers show best long-term performance in primary teeth. The cooperation has to be sufficient, at least during bonding and layering.
- The biggest effort is needed for resin composites. After rubber dam application and correct establishment of technique-sensitive adhesion, resin composites reach the level of compomers.
- Especially in severely decayed teeth and after endodontic treatment, preformed metal crowns should be taken into account as last and appropriate alternative to direct restorations for poli-caries patients.

Based on the high clinical success rates, compomers with self-etch adhesives can be recommended for restorative therapy in anterior and posterior primary teeth.

¹ Kilpatrick NM: Durability of restorations in primary molars. *J Dent* 1993;21:67-73.

² Mjor IA, Dahl JE, Moorhead JE: Placement and replacement of restorations in primary teeth. *Acta Odontol Scand* 2002;60:25-28.

³ Hickel R, Kaaden C, Paschos E, et al.: Longevity of occlusally-stressed restorations in posterior primary teeth. *Am J Dent* 2005;18:198-211.

⁴ Burke FJ, Fleming GJ, Owen FJ, Watson DJ: Materials for restoration of primary teeth: 2. Glass-ionomer derivatives and compomers. *Dent Update* 2002;29:10-17.

⁵ Krämer N, Frankenberger R: Clinical performance of a condensable metal-reinforced glass-ionomer cement in primary molars. *Br Dent J* 2001;190:317-321.

⁶ Frankenberger R, Krämer N, Graf A, Petschelt A: Cyclic fatigue of different glass-ionomers and compomers. *Dtsch Zahnärztl Z* 1999a;54:269-271.

- ⁷ Ostlund J, Moller K, Koch G: Amalgam, composite resin and glass-ionomer cement in Class II restorations in primary molars-a three year clinical evaluation. *Swed Dent J* 1992;16:81-86.
- ⁸ Espelid I, Tveit AB, Tornes KH, Alvheim H: Clinical behaviour of glass-ionomer restorations in primary teeth. *J Dent* 1999;27:437-442.
- ⁹ Hubel S, Mejare I: Conventional versus resin-modified glass-ionomer cement for Class II restorations in primary molars. A 3-year clinical study. *Int J Paediatr Dent* 2003;13:2-8.
- ¹⁰ Qvist V, Manscher E, Teglers, PT: Resin-modified and conventional glass-ionomer restorations in primary teeth: 8-year results. *J Dent* 2004b;32:285-294.
- ¹¹ Burke FM, Hamlin PD, Lynch EJ: Depth of cure of light-cured glass-ionomer cements. *Quintessence Int* 1990 ;21:977-980.
- ¹² Qvist V, Laurberg L, Poulsen A, Teglers PT: Class II restorations in primary teeth: 7-year study on three resin-modified glass-ionomer cements and a compomer. *Eur J Oral Sci* 2004a;112:188-196
- ¹³ Donly KJ, Segura A, Kanellis M, Erickson RL: Clinical performance and caries inhibition of resin-modified glass-ionomer cement and amalgam restorations. *J Am Dent Assoc* 1999;130:1459-1466.
- ¹⁴ Reichl FX, Durner J, Kehe K, et al.: Toxicokinetic of HEMA in guinea pigs. *J Dent* 2002;30:353-358.
- ¹⁵ Ernst CP, Weckmuller C, Willershausen B: Primary tooth build-ups using compomers. *Schweiz Monatsschr Zahnmed* 1995;105:665-671.
- ¹⁶ Garcia-Godoy F: Resin-based composites and compomers in primary molars. *Dent Clin North Am* 2000;44:541-570.
- ¹⁷ Tran LA, Messer LB: Clinicians' choices of restorative materials for children. *Aust Dent J* 2003;48:221-232.
- ¹⁸ Roeters JJ, Frankenmolen F, Burgersdijk RC, Peters TC: Clinical evaluation of Dyract in primary molars: 3-year results. *Am J Dent* 1998;11:143-148.
- ¹⁹ Attin T, Opatowski A, Meyer C, et al.: Three-year follow up assessment of class II restorations in primary molars with a polyacid-modified composite resin and a hybrid composite. *Am J Dent* 2001;14:148-152.

Quality of Class II compomer fillings after five years

C. Benz, R. Hickel

Department of Operative Oentistry and Periodontology, LM University Munich, Germany

Background

Since they first appeared on the market in the mid-1990s, compomers have had a changeable fate. Compomers were the first materials with which relaxation of the strict conditions associated with the use of classical composites (light-curing wedge, transparent matrix, rubber dam) appeared possible, and accordingly, the first material of this type (Dyract®) and compomers overall became very popular. The fact that the first-generation compomers were not the hoped-for alternative to amalgam but were limited primarily to restoration of deciduous teeth and cervical defects contributed to this. In the late 1990s, the first generation was followed by Dyract®AP, a version with somewhat improved mechanical properties. This allowed restoration of major defects in posterior second dentition teeth. Dyract®eXtra (DENTSPLY DeTREY, Konstanz), a third-generation compomer, was first marketed in 2003. This restorative material was shown to have a protective action against caries in an in-situ experiment. [Lennon A et al.]¹

The aim of this study was to evaluate major Class II restorations of permanent teeth with Dyract®AP after five years.

Material and method

34 patients took part in the study and underwent Class II restoration of 42 cavities. Apart from the occlusal surface, nine cavities involved one other tooth surface, 21 had two other surfaces, eight had three and four had four other surfaces.

The inclusion criteria were: carious defects or fillings requiring revision. The oro-vestibular width of the cavities was at least 1/3 but on average less than 2/3 of the vestibular tooth width. The teeth were clinically asymptomatic, reacted sensitively to cold testing and had antagonistic and proximal contact. The pulp was not exposed during preparation in any of the patients. The exclusion criteria were: persons under 16 years, pregnant patients and patients with systemic diseases.

All of the restorations were placed by one clinician under practice conditions.

Two calibrated investigators evaluated the restorations independently after a week and then annually until five years after application. The evaluation was carried out using modified Ryge USPHS criteria, using the original shape for comparison of anatomic form.

Results

Of the 34 patients who took part in the study originally, 28 subjects with 32 restorations could be followed up after five years. Ten restorations involved premolars and 22 involved molars. The reasons why nine restorations could not be evaluated after five years were two fractures and seven cases where the patients failed to reattend.

Table 1 shows the evaluation results for different Ryge USPHS criteria. With regard to the criteria “shade match” and “marginal discoloration” the difference between baseline and the five-year result was statistically significant, but the differences in the criteria “marginal integrity” and “anatomic form” were not greater than chance. After five years, all the evaluations were “clinically acceptable”.

With regard to restoration size, jaw (maxilla or mandible) and type of tooth (molar or premolar) there was no statistically significant difference for any of the evaluation criteria between baseline and five-year results.

All of the examined teeth were clinically asymptomatic after five years, reacted sensitively to cold testing and proved to be clinically and radiographically free from caries in the region of the restoration.

After five years two out of 35 restorations were revised (one premolar, one molar). This gives a failure rate of 5.7 % or an annual loss of 1.4 %.

The evaluation criteria in the four categories were:

1. Shade match

- A perfect shade match between tooth and restoration
- B slight difference
- C obvious difference evident at examination distance
- D obvious difference evident at speaking distance

2. Marginal discoloration

- A no discoloration in the entire visible marginal area
- B slight discoloration removable by polishing
- C severe discoloration in the enamel area
- D severe discoloration with dentine involvement

3. Marginal integrity

- A no gap palpable with a probe in the entire accessible marginal area
- B slight gap removable by polishing
- C obvious marginal gap
- D marginal gap extends to the base of the cavity, the restoration may be loose or demonstrate secondary caries

4. Anatomic form

- A original volume preserved
- B slight loss of substance
- C marked loss of substance
- D loss of substance requiring immediate replacement of the restoration.

	Baseline				5 years				Significant difference
	A	B	C	D	A	B	C	D	
Shade match	32	0	0	0	23	9	0	0	yes
Marginal discoloration	32	0	0	0	19	1	0	0	yes
Marginal integrity	32	0	0	0	28	4	0	0	no
Anatomic form	25	7	0	0	23	9	0	0	no

Table 1 Results of evaluation of the 32 restorations followed up after five years.

Conclusions

Compomers are materials that vary greatly in their physical and mechanical characteristics. They have proven effective in deciduous teeth and cervical restorations. Many compomers are not suitable for load-bearing restorations in the posterior region and have not been approved for this. Five-year data are now available for Dyract®AP in Class II restorations in permanent teeth. The success rates are comparable to those obtained with amalgam fillings and hybrid composites, thus confirming the suitability of this material for stress-bearing restorations.

¹ Lennon AM, Wiegand A, Buchalla W, Attin T: Approximal caries development in surfaces in contact with fluoride-releasing and non-fluoride-releasing restorative materials: an in-situ study. *Eur J Oral Sci* 2007;115:497-501.

Approximal caries development in surfaces in contact with fluoride-releasing and non-fluoride-releasing restorative materials: an in-situ study

*A.M. Lennon, A. Wiegand, W. Buchalla, T. Attin
European Journal of Oral Sciences 2007;115:497-501*

Background

Restorative treatment of the posterior teeth is still one of the most common procedures in the dental office despite the increasing emphasis on prophylaxis – whether through regular professional dental prophylaxis or education in better oral hygiene and improved tooth-protective diet.

If a Class II cavity bordering approximally on an intact tooth surface must be treated (Fig. 1), the question arises whether in addition to prophylactic measures, such as the use of floss and interdental brushes, the choice of filling material can also have an effect on the potential for developing caries on this approximal surface.

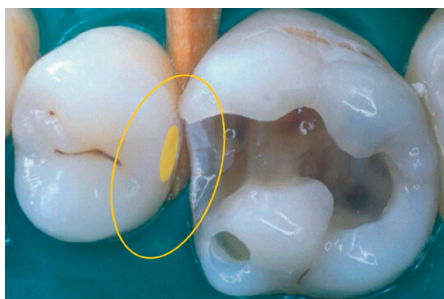


Figure 1
Intact approximal surface adjacent to a Class II cavity

An extensive literature review by Wiegand et al.¹ has indicated that Glass-ionomers and their modified forms and compomers may have a potential caries-protective effect.

Unlike Glass-ionomers and conventional compomers, the compomer Dyract®eXtra is indicated for occlusal stress-bearing posterior

fillings. The predecessor product Dyract®AP demonstrated results after 4 years that were equivalent to those of a fine hybrid composite in a clinical study at the University of Munich.²

Aim

The effect of the filling material on the development of enamel caries on approximal surfaces was tested by Lennon et al. in a volunteer study (in-situ).³

Method

As part of the simulation of the approximal contact flat enamel specimens on the one hand and hemispheric specimens with flattened contact surfaces on the other were prepared from two filling materials (Dyract®eXtra and composite); enamel controls were also prepared. A flat intact enamel surface was placed in contact with a test specimen in an intra oral appliance (Fig. 3) with four chambers on each side, one specimen per chamber (Fig. 2).

Dyract®eXtra was applied in three chambers on one side and the composite in three chambers on the other side. The fourth chamber on each side was given a control specimen (enamel-on-enamel) in alternating positions (Fig. 2, Fig. 3).




Figure 2

Approximal contact of enamel with specimen in the four chambers on one side



Figure 3

Intra oral appliance with four test chambers on each side

To test whether the effect of the filling material would potentially be suppressed through regular use of fluoridated toothpaste, all specimens were treated twice daily for a period of 4 weeks with a slurry of fluoridated toothpaste.

For 4 weeks, the 20 volunteer subjects wore the prepared appliance. Twice a day they removed the intra oral appliance for cleaning for 2 minutes. When cleaning was finished, they reinserted the appliance and rinsed it with a fluoridated toothpaste foam for 30 seconds before spitting it out. This simulated regular teeth cleaning without approximal hygiene.

In addition, the braces were placed five times per day in a 10 % sucrose solution to simulate meal times and provide appropriate nutrition for the attached plaque.

The test enamel surfaces were analyzed before and after by quantitative light-induced fluorescence (QLF™). This method permits changes in the enamel, such as one finds in initial enamel lesions, to be captured optically (Fig. 4) and quantitatively.

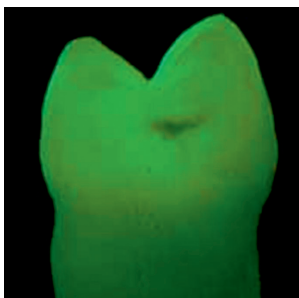
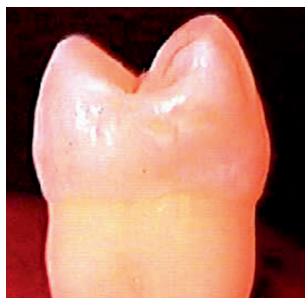
Fig. 4

*Initial enamel lesion:
visible light and in-
duced fluorescence
www.inspektor.nl*

The ΔQ (surface x mean fluorescence loss [% mm]) was determined as a measure of carious activity.

Fig. 5 shows by way of example the comparison between Dyract®eXtra and the composite. In the composite (lower row) there is an evident loss of fluorescence (changes in the enamel).




Figure 5

Dyract®eXtra (above) and composite: before (left column) and after the test period, and also as a pseudocolor image (right columns).³

Results

The statistical analysis of the results indicated that:

- Dyract®eXtra effectively supported the prevention of approximal caries
- this effect was particularly remarkable in those 50 % of the test subjects with the highest carious activity (defined as high risk group)
- even the control specimens (adjacent teeth) on the Dyract®eXtra side displayed a trend ($p = 0.051$) toward fewer enamel changes than those on the composite side
- the protective effect of Dyract®eXtra emerged over the sole use of fluoridated toothpaste
- the composite showed no protective effect.

Therefore the choice of filling materials does influence the development of enamel lesions on approximal surfaces.

Conclusion

The choice of Dyract®eXtra in restorative treatment for Class II cavities in patients prone to risk of caries is therefore advisable as an additional care against the onset of new approximal caries.

¹ Wiegand A, Buchalla W, Attin T: Review on fluoride-releasing restorative materials – Fluoride release and uptake characteristics, antibacterial activity and influence on caries formation. *Dent Mater* 2007;23:3;343-362.

² Benz C, Hickel R: The quality of Class II compomer fillings after 4 years. *DZZ* 2005;60:4;200-202.

³ Lennon AM, Wiegand A, Buchalla W, Attin T: Approximal caries development in surfaces in contact with fluoride-releasing and non-fluoride-releasing restorative materials: an in-situ study. *Eur J Oral Sci* 2007;115:497-501.

Restoration materials for primary molars – results from a European survey

V. Buerkle, J. Kuehnisch, M. Guelmann and R. Hickel
Journal of Dentistry 2005;33:275-281

Objective

The aim of this study was to obtain an overview of the materials and restorative techniques taught for Class I and Class II restorations in primary molars of different European departments for paediatric dentistry.

Methods

The forms were sent to the chairmen of the departments of paediatric dentistry or – when included into the department for operative dentistry – to the director of 200 universities in 32 European Countries. The questions concerned the preferred materials and techniques, as well as the indications or contraindications for the use of the different tooth coloured materials.

Use of restoration materials

When asked if amalgam was still the preferred material for restorations in primary teeth, the answers varied: the highest rate was seen in eastern universities, whereas none of the Scandinavian universities regarded amalgam as the preferred material (Fig. 1). Thirty-three percent of the European universities and 66 % of the German dental schools preferred compomers as favourable for Class I and II restorations in primary molars. Detailed information about recommendations of each material are shown in Table 2. All universities teach GIC, compomers and/or composites as alternative materials for primary molars.

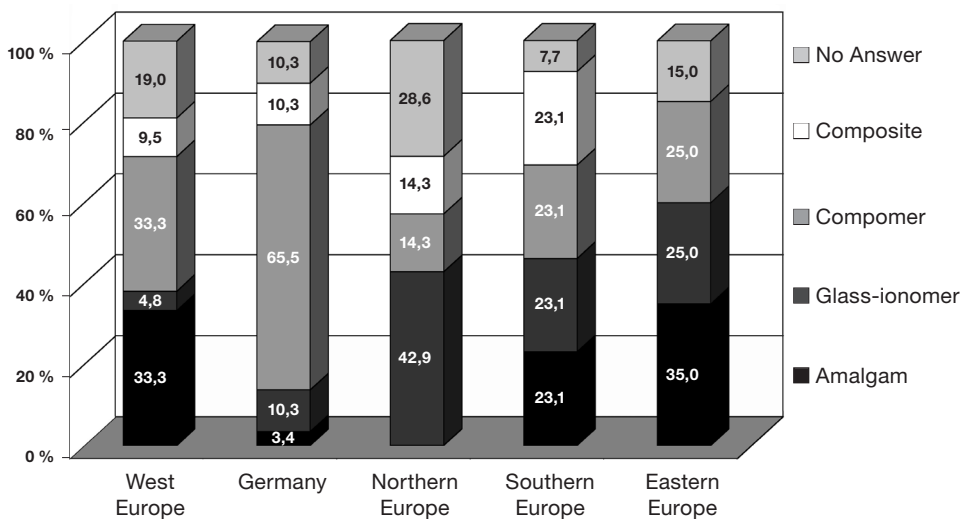
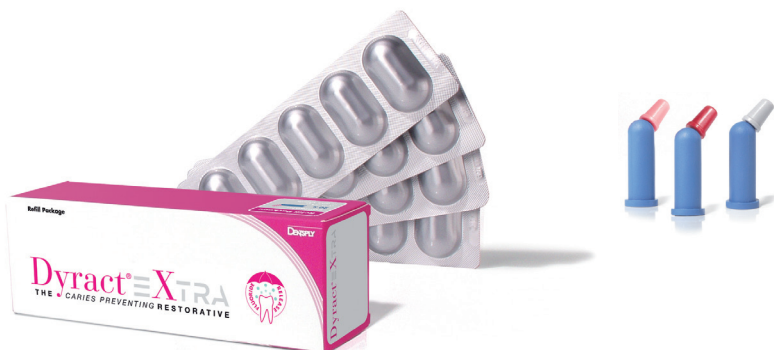

Figure 1

Preferred materials for posterior Class I and II restorations in primary molars.

Conclusions

From the data presented in this study it is obvious that there are large differences among dental schools in Europe in relation to teaching and use of filling materials in the primary dentition. Although amalgam is no longer as popular in many areas as it used to be, it continues to be taught in many schools. In conclusion, it can be stated that tooth coloured filling materials have become more and more popular and that compomers play a major role among European dental schools.



Further Clinical Studies of Dyract®eXtra (DX), Dyract®AP (DA), Dyract® (D)

Reference	Material	Indication	Period (Years)	Success Rate*	Failure Rate per Year
Hickel/Manhart, 2004 ¹	DX	Class I, II	1,5	98%	1.5%
Jedynakiewicz, 2002 ²	DA	Class I, II	3	100%	0%
Toh, 2001 ³	DA	Class I, II	1	100%	0%
Roeters, 1996 ⁴	D	Class I, II**	2	95%	2.5%
Marks, 1999 ⁵	D	Class II**	3	94%	2.0%
van Dijken, 1999 ⁶	D	Class III	5	92%	1.6%
Prati, 1998 ⁷	D	Class III & V	3	100%	0%
Elderton, 1997 ⁸	D	Class V	3	100%	0%
Abdalla, 1997 ⁹	D	Class V	2	100%	0%
Jedynakiewicz, 1997 ¹⁰	D	Class V	3	98%	0.6%
Barnes, 1997 ¹¹	D	Class V	2	97%	1.5%
Hellwig, 2004 ¹²	DX	Class V	1	98%	2%

* Minimum success rates according to the American Dental Association (ADA) in clinical trials are for Class V restorations: 95% at 6 months and 90% at 18 months. For clinical investigations on Class I and II the minimum success rate is 90% to 95% depending on the type of failure. Bulk fractures are not acceptable.

** Deciduous molars

¹ Manhart J, Chen HY, Neuerer P, Thiele L, Jaensch B, Hickel R: Klinische 18 Monatsergebnisse von Dyract eXtra im Molarenbereich Poliklinik für Zahnerhaltung und Parodontologie, LMU München.

² Jedynakiewicz, NM, Martin N, Fletcher JM: A clinical evaluation of a posterior compomer restorative at 3 years. *J Dent Res* 2002;81:Special Issue A.

³ Toh CG, Abu-Kasim NH: Clinical evaluation of a compomer in the restoration of class I and II cavities in Permanent Posterior Teeth: 1-year results. Dept of Conservative Dentistry, Faculty of Dentistry, University of Malaya, MALAYSIA.

⁴ Roeters FJM, Burgersdijk RCW, Frankenmolen FWA: Two-year's clinical evaluation of Class I and II compomer restorations in deciduous molars. University of Nijmegen, Nijmegen, Netherlands.

⁵ Marks LAM, Weerheijm KL, van Amerongen WE, Groen HJ, Martens LC: Dyract versus Tytin Class II Restorations in Primary Molars: 36-months evaluation. *Caries Res* 1999;33:387-392.

⁶ van Dijken, JWV: Longevity of new hybrid restorative materials in Class III cavities. *Eur J Oral Sci* 1999;107:215-219.

⁷ Prati C, Chersoni S, Cretti L, D'Arcangelo D: A three year clinical study on Class III Class V restored with Dyract compomer. 1998 School of Dentistry, University of Bologna.

⁸ Elderton, RJ: 3-year retention of cervical compomer restorations in non undercut cavities. *J Dent Res* 1997;76:162 Abstr.No. 1185.

⁹ Abdalla, AI, Alhadainy, HA: Clinical evaluation of hybrid ionomer restoratives in class V abrasion lesions: Two year results. *Quintessence Int* 1997;28:255-258.

- ¹⁰ Jedyakiewicz, NM, Martin N, Fletcher JM: A 3-year clinical evaluation of a compomer restorative. *J Dent Res* 1997;76:162 Abstr.No. 1189.
- ¹¹ Barnes DM, Blank LW, Gingell JC, Barnes CA: A 24-month clinical evaluation of Dyract light cured compomer restorative. *J Dent Res* 1997;76:293 Abstr.No. 2205.
- ¹² Hellwig E, Auschill T, Kopp MC: Praxisstudie zum klinischen Langzeitverhalten eines Kom-pomers in Kombination mit einem selbstätzenden Adhäsiv bei Klasse-V-Kavitäten. *Quintessence* 2007;58(6):611-617.

The better restorative for patients needing eXtra care!

	Especially important for ...				Results from ...		
	Children	Teenagers	Adults with high risk of caries	Elderly patients	Glass-ionomers	Composites	Dyract ^e Xtra
Long term Fluoride release + Buffer capacity	✓	✓	✓	✓	+	-	+
Longevity	✓	✓	✓	✓	-	+	+
Aesthetic		✓	✓		-	+	○
Material flexibility due to a low E-Modulus				✓	-	-	+
Xerostomia (Mouth dryness)				✓	-	+	+
Time-saving treatment	✓			✓	+	-	+

Dyract[®] eXTRA
THE CARIES PREVENTING RESTORATIVE

DENTSPLY DeTrey GmbH
De-Trey-Str. 1
78467 Konstanz
GERMANY
www.dentsply.eu
Phone +49 (0) 75 31 5 83-0

DENTSPLY Ltd
Building 1
Aviator Park, Station Road
ADDLESTONE, KT15 2PG
UNITED KINGDOM
Phone +44 (0) 19 32 85 34 22

DENTSPLY UK Export (MEA/CIS)
Building 1
Aviator Park, Station Road
ADDLESTONE, KT15 2PG
UNITED KINGDOM
Phone +44 (0) 19 32 85 34 22

For better dentistry
DENTSPLY