

Creating Natural-Looking Composite Restorations

Using Different Layering Techniques, Materials and the Erbium YAG Laser

Daniel H. Ward, DDS

Introduction

Improved materials and instruments help us to produce restorations that are natural looking. Composite systems have been developed that have optical qualities similar to the tooth structure they are replacing.¹ Composite materials with dark opacity and fluorescence are useful to recreate dentin.² Enamel replacing materials with added translucency and opalescence give the outer surface of the tooth a realistic appearance.³ Layering multiple shades with differing hue, chroma and value can give the tooth a more 3-dimensional look.⁴ Composites have been developed with differing approaches using two, three, or more layers. Having multiple systems can be beneficial.

Recently a new laser has been introduced at a significantly lower cost allowing it to be incorporated into more dental offices (**Fig. 1**). (LiteTouch, AMD LASERS) Being able to quickly prepare teeth often without anesthesia has been a significant advantage of using hard tissue lasers.⁵ Small to medium sized restorations can often be prepared without the use of local anesthetics. Let's examine how these new materials and technologies can be used.

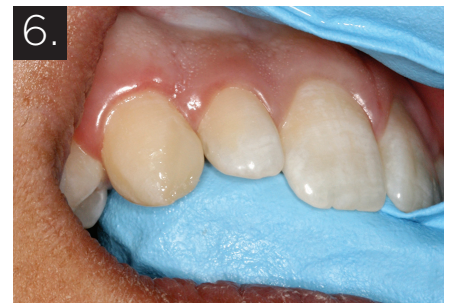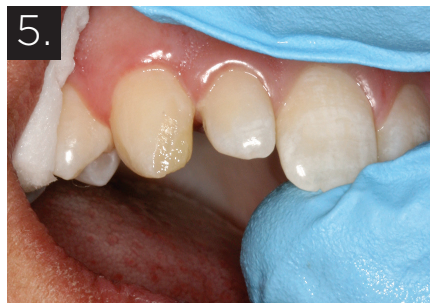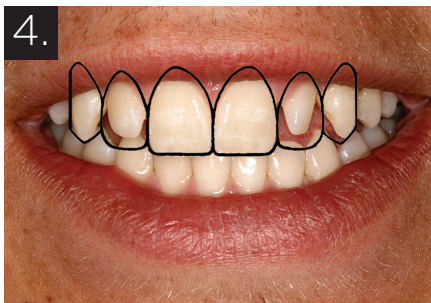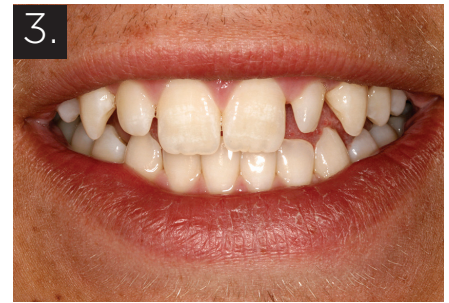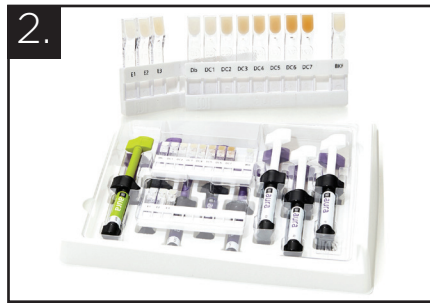
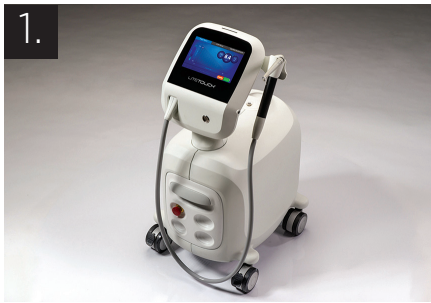Layered Restorations

Layered restorations are helpful in the anterior area to emulate the appearance of natural teeth. Restorative materials should mimic the tooth structure they replace. The deepest part of the restoration should be dark, more opaque and very high in chroma. Unfortunately there are few dentin shaded composites that truly match dentin. Very intense yellow/brown materials are needed.⁶ One system which is excellent for matching tooth structure is Aura (Aura, SDI) (**Fig. 2**). The

system originally had two materials, a dentin and an enamel replacement material, but an optional middle layer has been added. This helps to block the intense chroma of the dentin and blend the restoration color better. It also helps to make the exact thickness of the dentin and enamel shade layers less critical. The dentin shades do not coincide with any standard shading system but differ in the intensity of the chroma, ranging from Db, D1 to D7. As you build up the restoration, the material should become lighter, more translucent, opalescent and have smaller filler particles. The Aura system has an optional intermediate layer which is a multi-purpose composite MC2-5. The final layer enamel layer is a microfill and it comes in three shades. It is translucent and polishes well.

3-Layered Composite Restorations Case Presentation

A 15-year-old male presented to the office with peg lateral incisors and twisted maxillary canines (**Fig. 3**). His mother was interested in closing the spaces between his teeth. The sizes of the teeth were measured and it was determined that the central incisors were of normal size relative to the face. The widths available for the lateral incisors were deemed to be 70% of the frontal view widths of the central incisors. The widths of the maxillary canine teeth were also deemed to be 70% of the frontal view widths of the lateral incisors. This follows the recommendations of proportional smile design using the RED Proportion which states that the frontal view width proportions of the anterior teeth should remain constant as you move distally.⁷ The photograph with template demonstrates the ability to add to the lateral incisor and the canine and give a well-proportioned smile that matches the face (**Fig. 4**).⁸



The surface of the maxillary right canine was lightly roughened using a very fine diamond to areas to be bonded (201.3VF, Premier Dental). The entire surface was etched with phosphoric acid for 20 seconds, washed and dried thoroughly. A universal dentin bonding agent was brushed onto the surface for 20 seconds, the solvent evaporated and the area light cured (Universal Bond, BISCO Dental). The first increment added was the dentin layer. This layer is darker than the desired restoration but more opaque in order to block light from shining through the entire restoration and prevent a gray appearance. Dentin shade 6 was used since it mimics the shade of the natural dentin (**Fig. 5**) (Aura, SDI). The second increment added was multi-purpose composite shade MC-3 (**Fig. 6**) (Aura, SDI). White, orange and brown tints were painted over the second increment to characterize and mimic the shade patterns of the adjacent teeth (Shade modification tints, SDI). Finally an enamel shade layer E-1 was added to cover the entire restoration and build to full contour (**Fig. 7**). The restoration was shaped using diamonds and finishing carbides. Finishing and polishing was completed for the canine. The process was completed for the right maxillary lateral incisor (**Fig. 8**). Then the left canine and lateral incisor were restored in a similar fashion (**Fig. 9**).

Erbium Yag Lasers

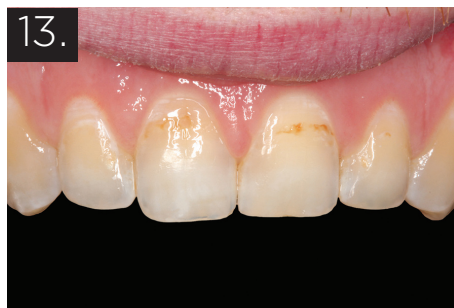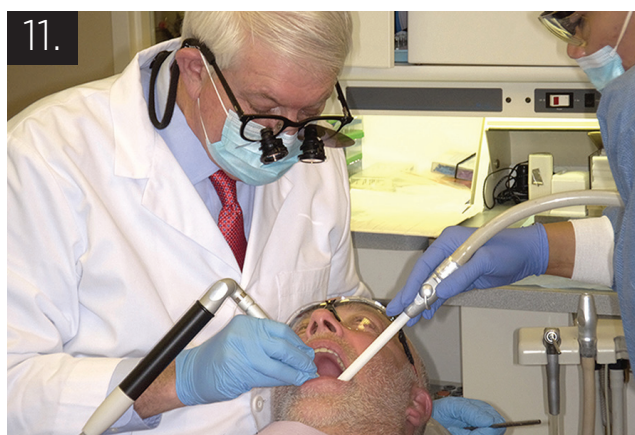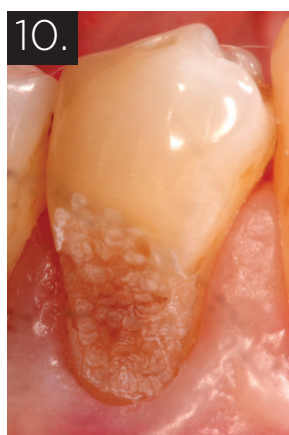
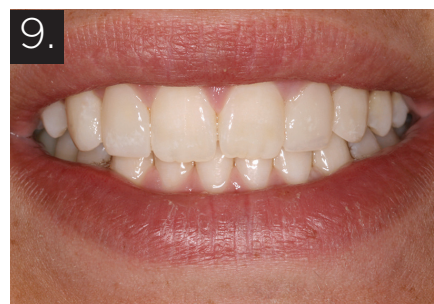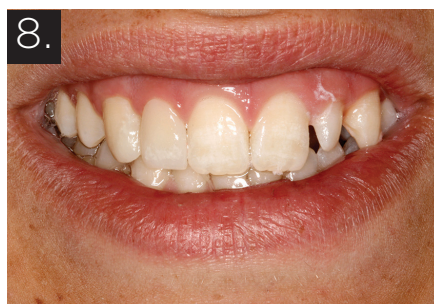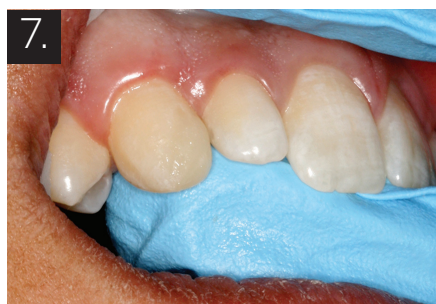Erbium lasers deliver pulsed energy onto the water, containing surface of the tooth and the water is vaporized ablating the

surrounding tooth structure. Preparation is accomplished by a series of pulsed energy emissions resulting in multiple small dot-shaped areas of tooth removed on the surface of the tooth (**Fig. 10**). The effect is very superficial with less vibration and heat.⁹ A primary advantage of tooth preparation with erbium-YAG is often preparation can be achieved with little or no anesthesia.

It is important to start with very low energy for the first minute to condition the pulp so that there is no discomfort during preparation. The lowest energy to accomplish the preparation is best and is controlled by the pulsing frequency and the power setting. The laser handpiece does not touch the tooth during preparation. The optimal distance from the tooth is best determined by listening for the pulses to be the loudest. The handpiece is constantly moved and the resulting tooth shaping is observed (**Fig. 11**). Preparation parallel to the tooth surface is best. Though actual preparation time may be longer than with a traditional high-speed handpiece, the time saved by not waiting for anesthesia often allows small restorations to be placed at re-care appointments rather than having to reappoint. Lasers are suitable for use in most direct restorative preparations but are best suited in Class I, III, and V restorations.

Clinical Use Of Hard Tissue Laser On Pitted Incisors With A 2-Layered Composite Technique

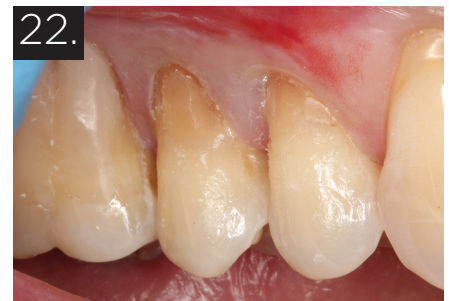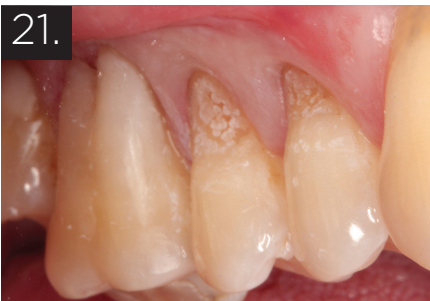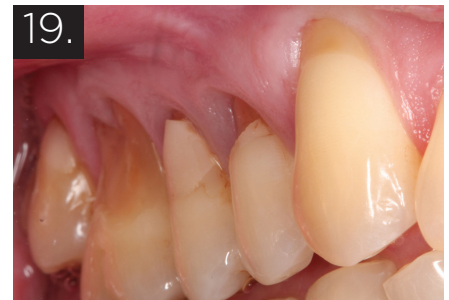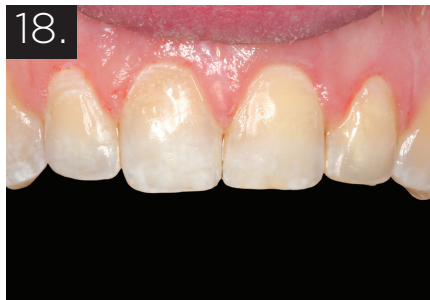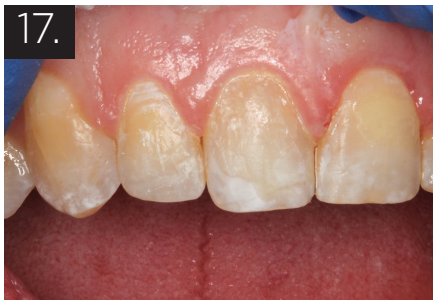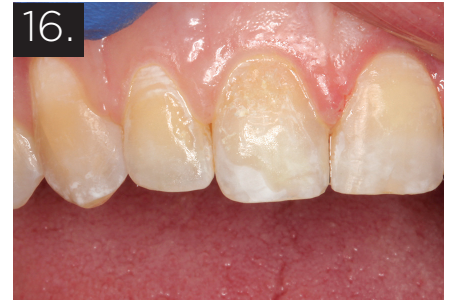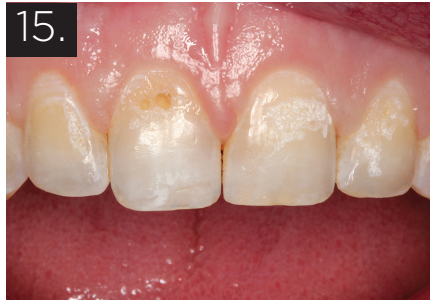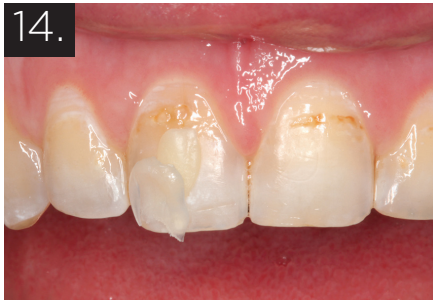Several companies produce composites designed to be used in a dual-layering technique. Some use a high chroma dark den-



tin and translucent enamel; others use a more opaque general purpose layer which is layered with a translucent enamel. One material which uses the later approach is Mosaic (**Fig. 12**) (Mosaic, Ultradent). A 27-year-old male presented to our office with pitted and stained incisors (**Fig. 13**). He was getting married in a few months and was concerned about the appearance of his smile in the wedding photographs. Composite from a new 2-component general purpose and enamel system was tried in and layered to determine the appropriate shades to be used (**Fig. 14**). The laser was used to prepare the affected areas of the facial surfaces of both central incisors and the left lateral incisor (**Fig. 15**). The left incisors were restored

using two layers. The surface was shaped using a very-fine flame shaped diamond (NeoDiamond 3512.10, Microcopy), a finishing carbide (NeoCarbide ET9, Microcopy), a finisher (Enhance, Caulk Dentsply) and two polishers. (DiaComp Feather Lite Medium and Fine Composite Polishers, Braseler). The right central incisor was built up first using the general purpose shade A-3 composite (**Fig. 16**) (Mosaic, Ultradent) and then the enamel shade ET composite (**Fig. 17**) (Mosaic, Ultradent). The restoration was shaped, finished and polished in a similar manner (**Fig. 18**).

→ from page 30



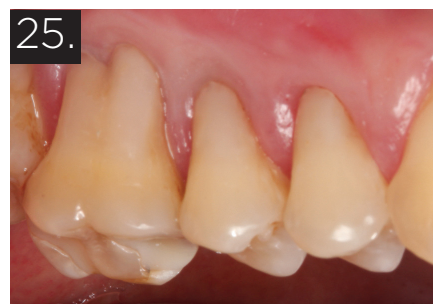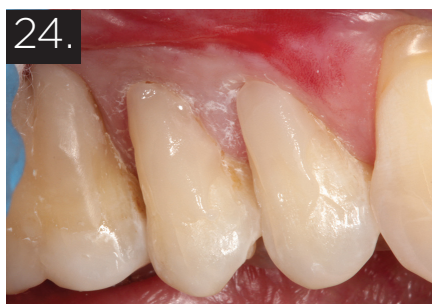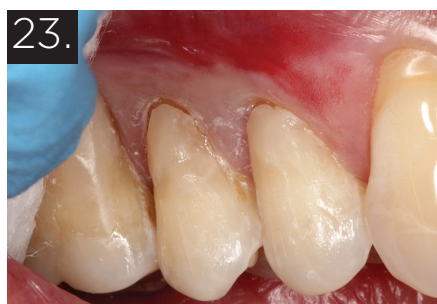Clinical Use Of Hard Tissue Laser On Class V Abfraction Lesions With A 3- Layered Multiple Products Composite Technique

Sometimes different composites from different manufacturers can be layered to best achieve a more natural appearance. A 52-year-old male presented to our office with severe abfraction lesions (Fig. 19). Several composite materials were tried in and three layers of different brand composites were selected (Fig. 20). The molar was first prepared using the laser and restored. Then the two premolars were prepared using the laser. (Fig. 21) The first layer of dentin material was used (Fig. 22) (Aura Dentin D-7). Then a layer of regular all purpose shade A-3 composite was used (Fig. 23) (Spectra TPH, Dentsply).

Finally a spherical composite shade A-2 was used for the enamel layer (Fig. 24) (Esthelite Sigma Quick, Tokuyama). The composites were shaped, finished and polished. (Fig. 25).

Summary

Teeth are comprised of different components. In order to match the original appearance, restorative materials should be used that exhibit similar optical qualities as natural teeth. Selecting composite materials for each individual situation, based on physical properties as well as their opacity/translucency, gives the best results. The hard tissue laser can be very useful and comfortable for the patient. Often not having to anesthetize is a big advantage allowing more efficient use of



time. Incorporating new technology and materials into the practice can enhance productivity, increase self-satisfaction and better please our patients. **OH**

Oral Health welcomes this original article.

References

1. Baratieri LN1, Araujo E, Monteiro S Jr. Color in natural teeth and direct resin composite restorations: essential aspects. *Eur J Esthet Dent*. 2007;2(2):172-86.
2. Villarroel M, Fahl N, De Sousa AM, De Oliveira OB Jr. Direct esthetic restorations based on translucency and opacity of composite resins. *J Esthet Restor Dent*. 2011;23(2):73-87.
3. Blank JT. Simplified techniques for the placement of stratified polychromatic anterior and posterior direct composite restorations. *Compend Contin Educ Dent*. 2003;24:19-25.
4. Terry DA. Dimensions of color: creating high-diffusion layers with composite resin. *Compend Contin Educ Dent*. 2003;24:3-13.
5. Nazemismalman B, Farsadeghi M, Sokhansanj M. Types of lasers and their applications in pediatric dentistry: a review. *J Lasers Med Sci*. 2015;6(3):96-101.
6. Dietschi D, Ardu S, Krejci I. A new shading concept based on

natural tooth color applied to direct composite restorations. *Quintessence Int*. 2006;37(2):91-102.

7. Ward DH. Proportional smile design using the RED proportion. *Dent Clin North Am* 2001;45:143-154.
8. Ward DH. Smile Design by the Numbers. *Oral Health* 2015;105(4):80-86.
9. Stabholz A, Zeltser R, Sela M, Peretz B, Moshonov J, Ziskind D, Stabholz A. The use of lasers in dentistry: principles of operation and clinical applications. *Compend Contin Educ Dent*. 2003;24(12):935-48.



Dr. Ward is in private practice in Columbus, Ohio. He is a Diplomat of the American Board of Aesthetic Dentistry, a Fellow of the American Society for Dental Aesthetics, Fellow in the Academy of General Dentistry, Fellow in the American and International College of Dentists and a member of Catalyst Education. He has lectured extensively and authored numerous articles.

Email: dward@columbus.rr.com

NEWCOM
BUSINESS MEDIA INC.

oralhealth

Reprinted with permission from Oral Health Group Magazine -
A Newcom Business Media Inc Publication