

3MSM Health Care Academy

Digital Smile Design and 3MTM ClarityTM ADVANCED Ceramic Brackets: the perfect synergy



Riccardo Riatti, DDS, MS, Specialist in Orthodontics

Dr. Riatti received his Dental Degree from the University of Parma and his Orthodontic Degree from the University of Cagliari. Since 2008, he has been Visiting Professor at the School of Specialization in Orthodontics at the University of Trieste. He is a diplomate of the Italian Board of Orthodontics

(IBO) and a diplomate of the European Board of Orthodontists (EBO). His teaching topics are esthetics, digital technologies and compliance-free treatment. Dr. Riatti maintain a private practice in Reggio Emilia, Italy.

Introduction

Nowadays esthetics is becoming more and more important. Our patients ask for beautiful smiles and esthetic appliances.

In recent years, DSD (Digital Smile Design) has been used widely by prosthodontists¹ and it can also be a useful tool for orthodontists. This article describes a case in which DSD has been integrated into the diagnosis process in order to obtain a better orthodontic treatment plan.

Use of 3MTM ClarityTM Ceramic Brackets with hi-tech 3MTM UnitekTM Lateral Development Archwires and overlay intrusion arch permitted perfect control of tooth movement. It was possible to expand arches in a controlled manner, reducing negative buccal corridors and to open the bite without mandibular posterior rotation (important for sagittal chin projection).

Diagnostic description of the case

A female patient, aged 10.6 years at start of treatment, with Class II skeletal bases (ANB 5°) on an average angle pattern (SN-mandibular plane angle 34°) and with Class II molar and canine relationship.

Moderate crowding was present in the lower arch and mild crowding was present in the upper arch.

The patient was in late mixed dentition, lower second deciduous molars were still present but about to be shed. There was a lower midline shift of 2 mm to the right, a deep overbite with lower incisors at -4 mm to the APog line and upper incisors at 95° to the palatal plane.

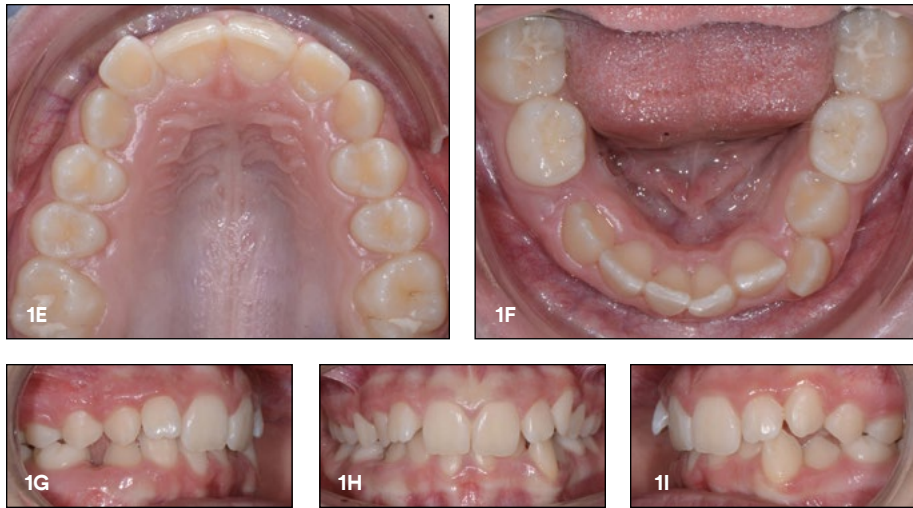
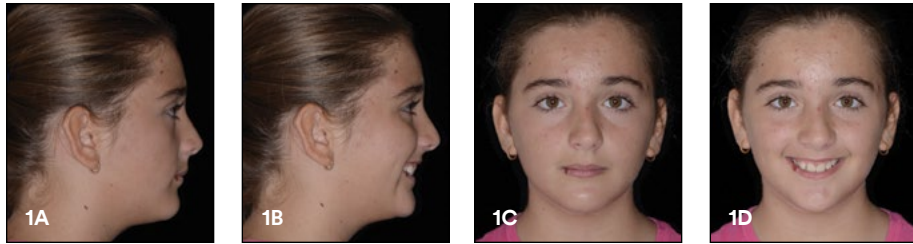

Figure 1A-I: Initial photos.

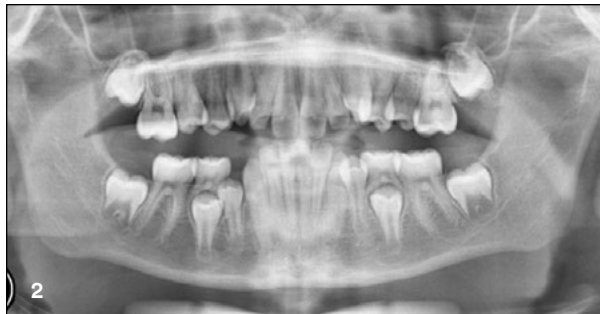

Figure 2: Initial X-ray.

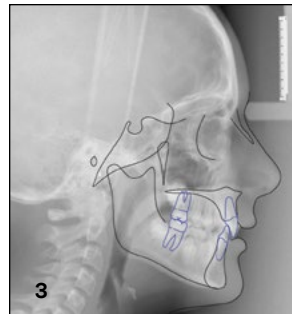


Figure 3: Initial cephalometric analysis and tracing.

Cephalometric Analysis		
	Norm	Pre-Treatment
SNA	82°	79°
SNB	80°	74°
ANB	2°	5°
SN-GoGn	32°	34°
Palatal-Mandibular °	28°	24°
U1 - APog	5 mm	1 mm
L1 - APog	2 mm	-4 mm
U1 - Palatal	110°	95°
L1 - Mandibular	95°	80°
U1 - L1	127°	161°

Table 1: Initial cephalometric analysis.

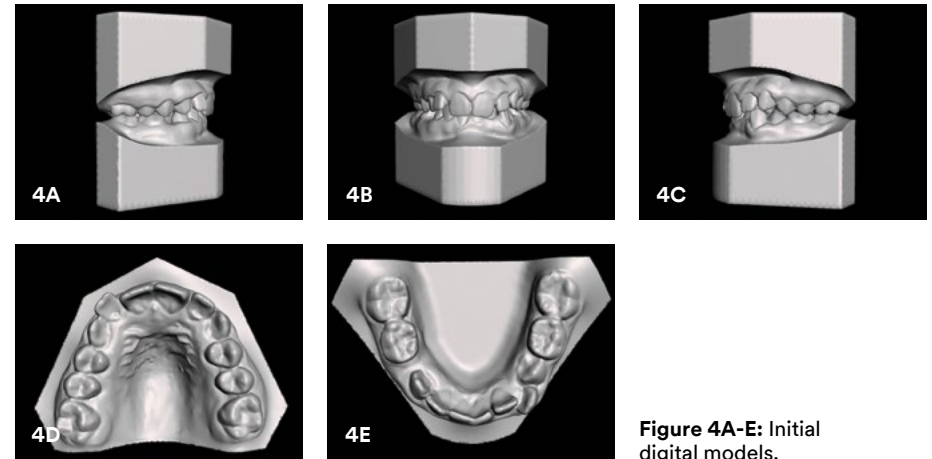


Figure 4A-E: Initial digital models.

Treatment plan

The chief concern of the patient was the gummy smile and the alignment of the anterior frontal teeth. Digital Smile Design orthodontic planning was adopted in order to plan how to improve smile esthetics. With this important tool it became evident that the upper central incisors had to be intruded 2 mm to reduce the gummy smile and that canine-premolar torque was too negative (Figure 5A-D). It was possible to plan the movement of every single tooth with high precision.

3M™ Clarity™ ADVANCED Ceramic Brackets were used in both arches to satisfy the patient's esthetic request while maintaining the high torque control characteristic of a pre-adjusted edge-wise fixed appliance system. A High Torque Prescription was chosen for the upper central incisors (+22°) and for the upper cuspids (+7°). A Roth Prescription (+8°) was chosen for the upper lateral incisors. In the lower arch the MBT prescription was used. The possibility to choose different torque values for every single tooth permitted a simplification of the finishing process by reducing the need for bends on the wire. The bite was opened principally through lower incisor absolute intrusion, avoiding premolar and molar extrusion, in order not to open the SN-mandibular angle. For this reason, use of intrusive mechanics was planned. Reducing profile convexity and increasing chin projection were both key points for the facial appearance of this patient.

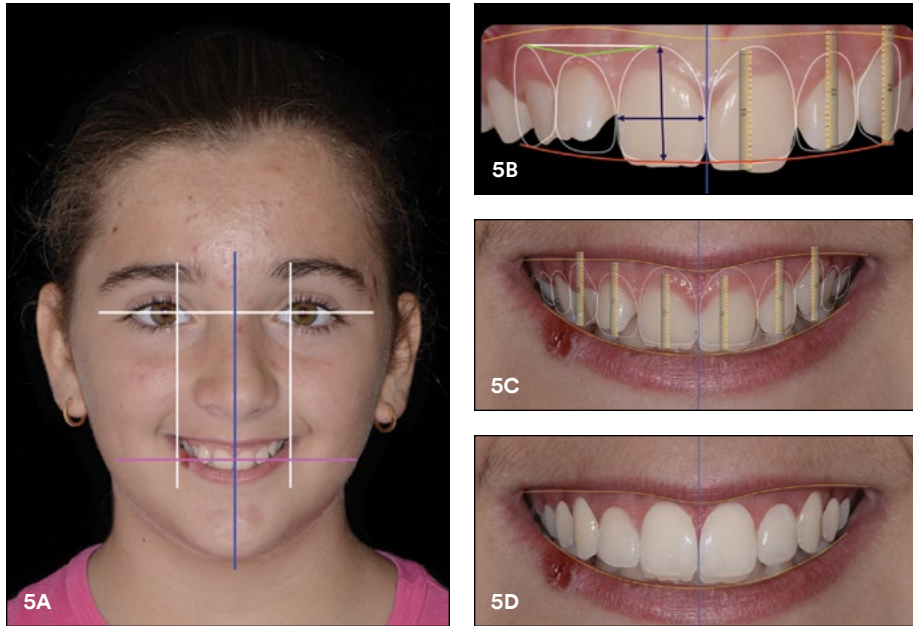


Figure 5A-D: DSD Digital Smile Design planning.

Treatment progress

- Archwire progression in the upper arch:
 - .014 Nitinol Lateral Development – Arch Form Size R28 (1.5 months)
 - .018 Nitinol Lateral Development – Arch Form Size R28 (1.5 months)
 - .016 x .022 Nitinol Lateral Development – Arch Form Size R28 (6 months)
 - .019 x .025 Nitinol Lateral Development – Arch Form Size R26 (3 months)
 - .019 x .025 Stainless Steel Posted – Individualized Arch Form (7 months)
- Archwire progression in the lower arch:
 - .014 Nitinol Lateral Development – Arch Form Size R28 (3 months)
 - .018 Nitinol Lateral Development – Arch Form Size R28 (1.5 months)
 - .016 x .022 Nitinol Lateral Development – Arch Form Size R28 (3 months)

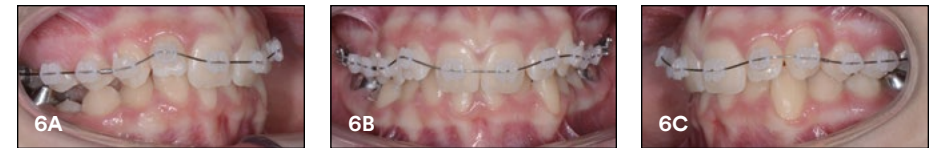

Figure 6A-C: Treatment progress photos: upper arch bonding.

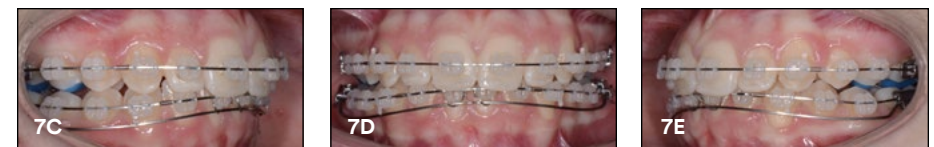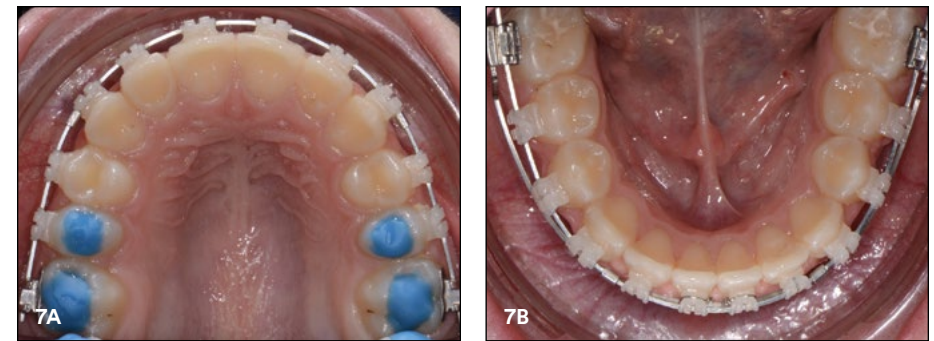


Figure 7A-E: Treatment progress photos: absolute intrusion of lower incisors.

With these archwires, an overlay intrusion arch (.019 x .025 Beta III Titanium) was used to obtain an absolute intrusion of the lower incisors (7.5 months).

.019 x .025 Nitinol Lateral Development – Arch Form Size R26 (3 months)

.019 x .025 Stainless Steel Posted – Individualized Arch Form (5 months)

- Upper posterior occlusal build-ups were built to control molar vertical position during the lower incisor intrusion phase.²
- Unilateral Class II elastics (Size ¼ in. - Force Rating Heavy 6 oz.) were used on the right side for 8 months, 12 hours a day, to center upper and lower midlines and to correct Class II molar and canine relationship.

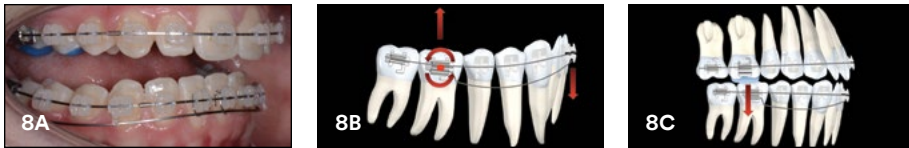

Figure 8A-C: Treatment progress photos: Overlay intrusion arch.

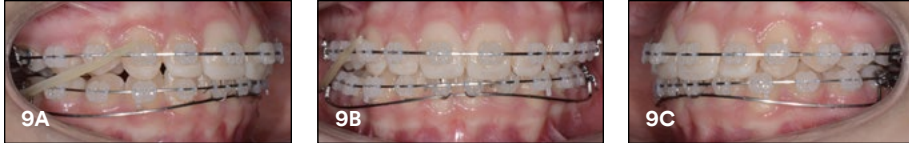

Figure 9A-C: Treatment progress photos: unilateral Class II elastics.

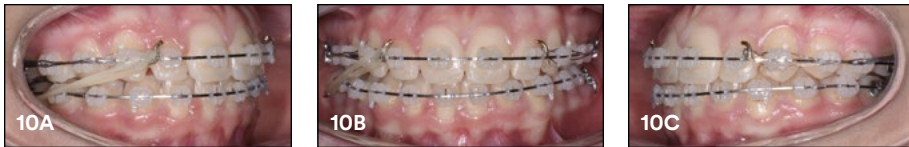

Figure 10A-C: Treatment progress photos: finishing.

Treatment results

Active treatment time was 19 months. No brackets were inadvertently debonded probably thanks also to the use of the 3M™ APC™ Flash-Free Adhesive System.³

An ideal occlusion⁴ was achieved; ANB decreased by 3°; SN-GoGn decreased by 2° and upper and lower incisors were well positioned in relation to the APog line. Upper incisors moved forward 4 mm; lower incisors 6 mm and the interincisal angle decreased by 35° improving lip fullness and profile appearance. The gummy smile was eliminated and the negative buccal corridors were reduced.

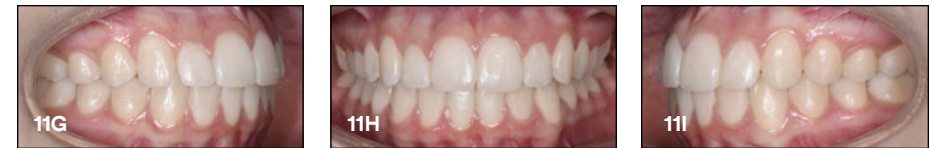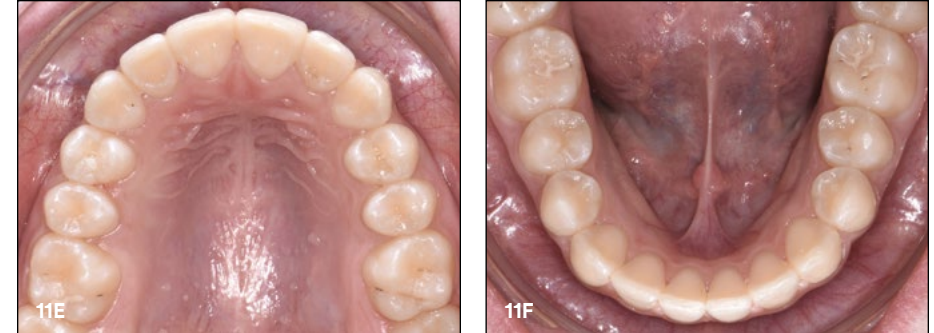
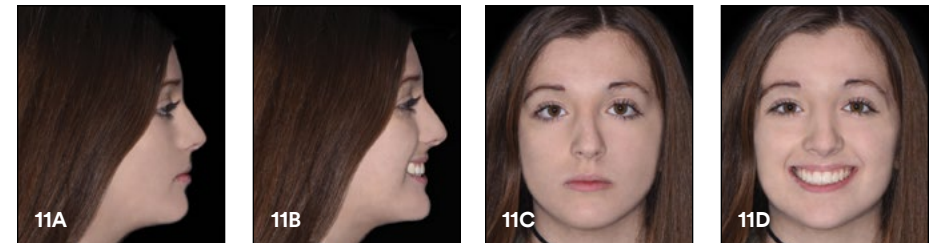


Figure 11A-I: Final photos.

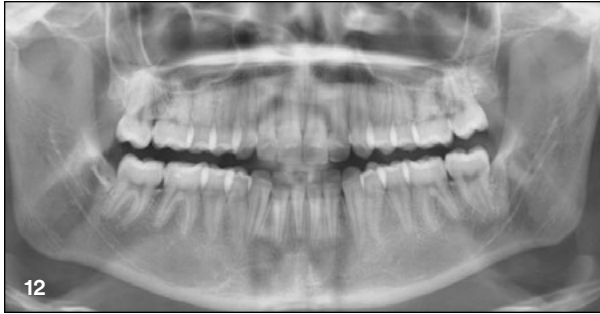


Figure 12: Final X-ray.

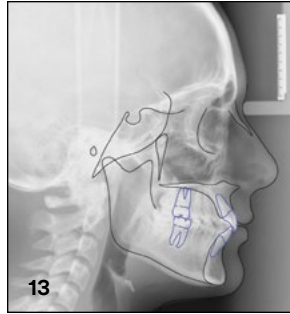


Figure 13: Final cephalometric radiograph and tracing.

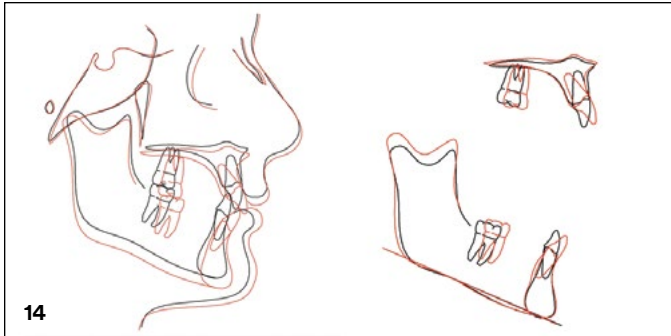


Figure 14: Cephalometric tracing superimpositions.

Cephalometric Analysis			
	Norm	Pre-Treatment	Post-Treatment
SNA	82°	79°	78°
SNB	80°	74°	76°
ANB	2°	5°	2°
SN-GoGn	32°	34°	32°
Palatal-Mandibular °	28°	24°	21°
U1 - APog	5 mm	1 mm	5 mm
L1 - APog	2 mm	-4 mm	2 mm
U1 - Palatal	110°	95°	114°
L1 - Mandibular	95°	80°	99°
U1 - L1	127°	161°	126°

Table 2: Final cephalometric analysis.

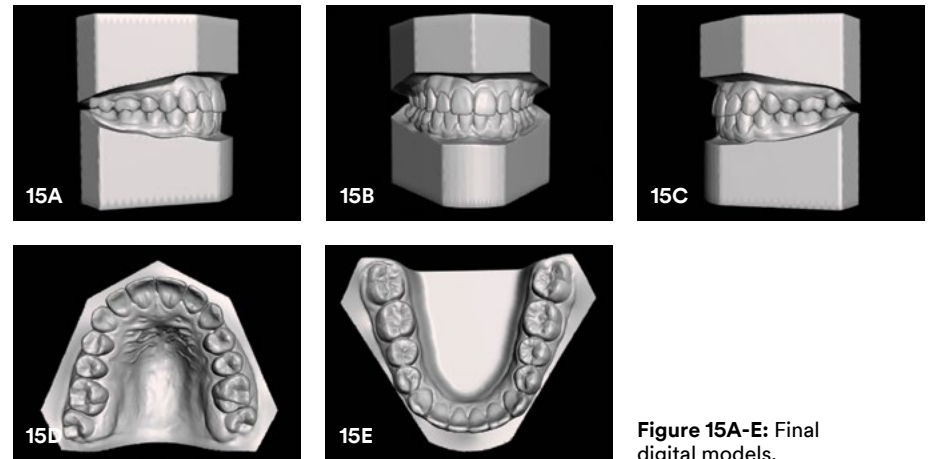


Figure 15A-E: Final digital models.

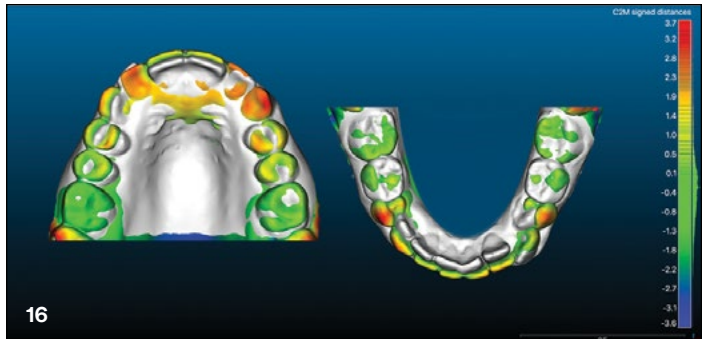


Figure 16:
Digital model
superimpositions.

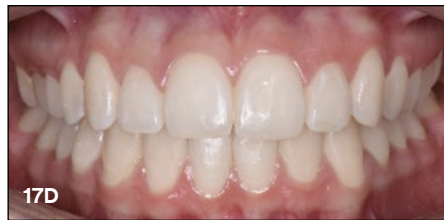
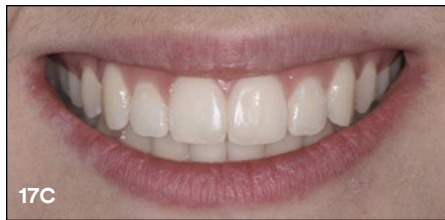
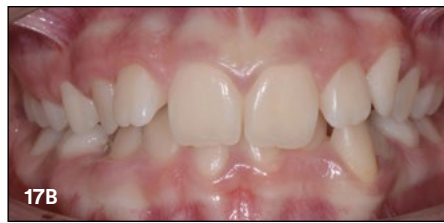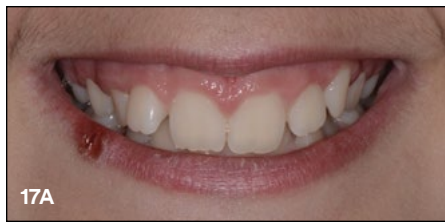Figure 17A-D: Initial vs. final photos.

Conclusions

The most significant result in this case was the improvement in smile esthetics. The detailed information provided by the Digital Smile Design orthodontic planning was of great help in obtaining the final result. The precise control of tooth movement was obtained with a combined use of Clarity ADVANCED Ceramic Brackets, hi-tech Unitek Lateral Development Archwires and Beta III Titanium intrusion arch. The patient was extremely satisfied with both the esthetics of the orthodontic appliance used and treatment result.

References

1. Coachman C, Paravina RD. Digitally Enhanced Esthetic Dentistry – From Treatment Planning to Quality Control. *J Esthet Restor Dent* 2016;28:S3-4
2. Vela-Hernández A, López-García R, García-Sanz V, Paredes-Gallardo V, Lasagabaster-Latorre F. Nonsurgical treatment of skeletal anterior open bite in adult patients: Posterior build-ups. *Angle Orthod* 2017;87:33-40.
3. Lee M, Kanavakis G. Comparison of shear bond strength and bonding time of a novel flash-free bonding system. *Angle Orthod* 2016;86:265-70.
4. Andrews LF. The six keys to normal occlusion. *Am J Orthod* 1972;62:296-309.

Case photos provided by Dr. Riccardo Riatti.