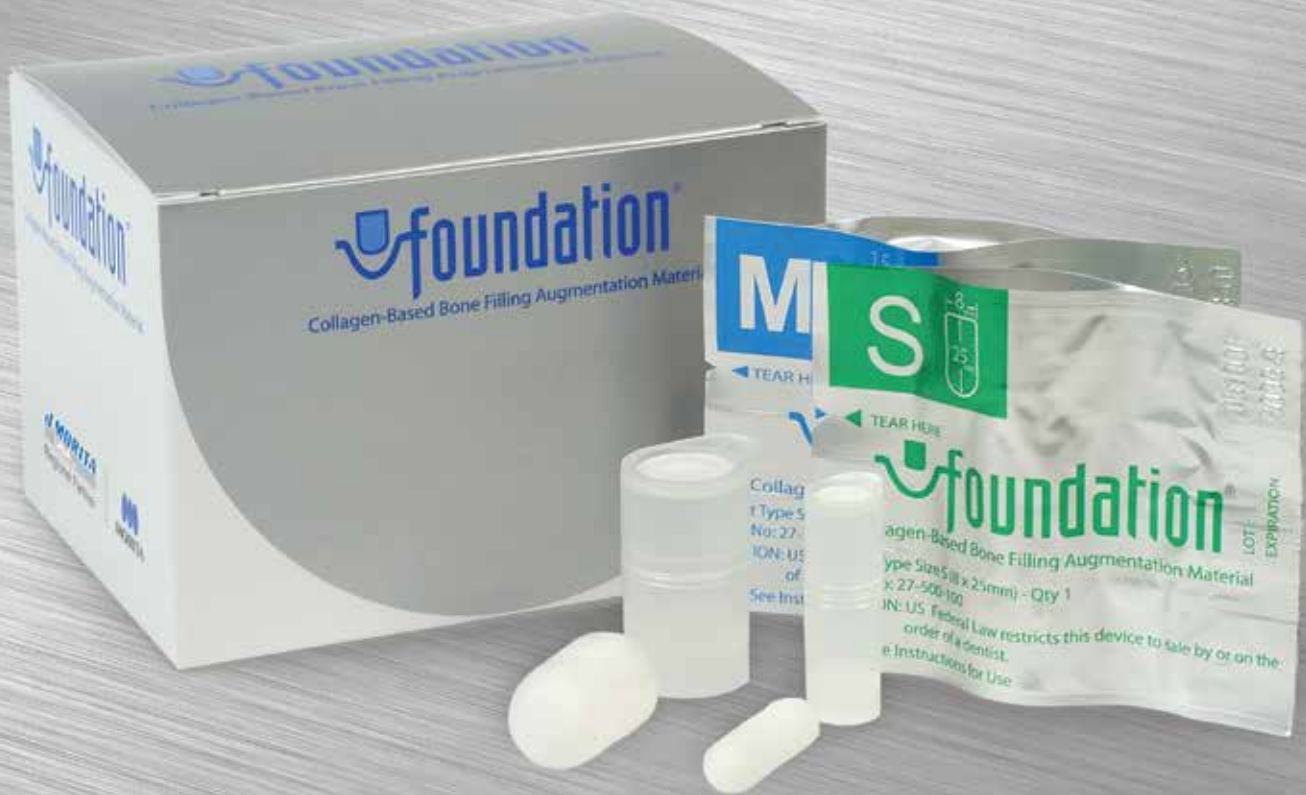



Foundation® Revolutionary Bone Augmentation Material

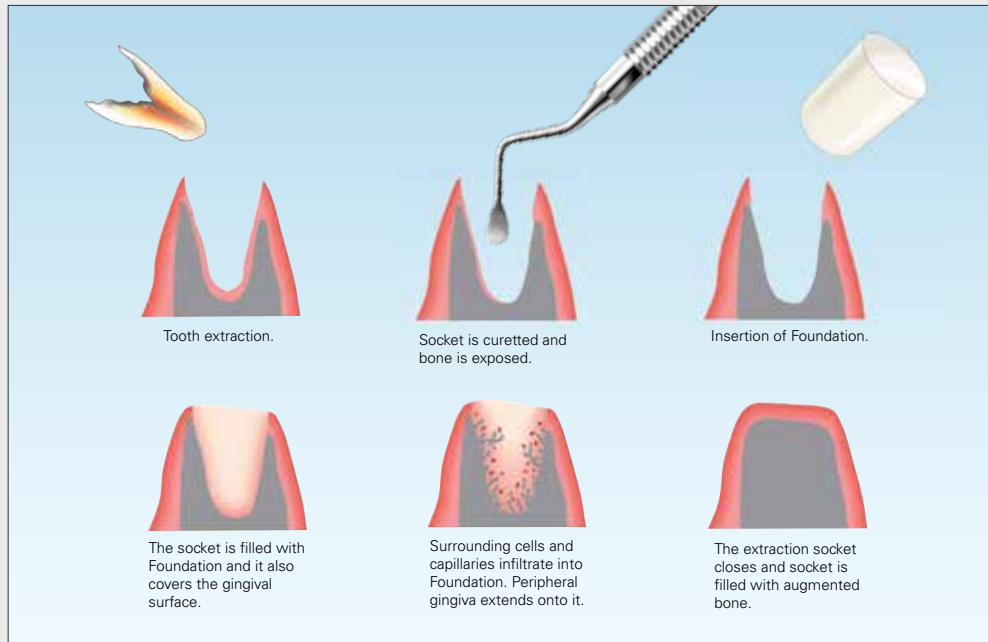
Thinking ahead. Focused on life.

J.MORITA
USA INC.

Regional Partner


MORITA

Easy Placement, Effective Results



Foundation is composed of atelo-collagen which has been cross-linked by heat treatment in order to achieve biocompatibility. The product is provided in a bullet shape for easy placement into the extraction socket. It consists of fibrillar and heat-denatured atelo-collagen. Fibrillar atelo-collagen provides scaffolding for surrounding cells and the heat-denatured atelo-collagen stimulates infiltration of the cells into the product. Contents are sterile and non-pyrogenic.

Histology, University of Rochester, Eastman Institute for Oral Health Research

Biopsies from the healed extraction sites were taken using trephine biopsy osteotomy at 8 weeks after the placement of Foundation. The cylindrical bone segments obtained were scanned with high resolution micro-computed tomography to determine bone volume and density. The specimens were decalcified using 10% EDTA, embedded, sectioned, and stained with hematoxylin and eosin. New bone formation was identified using polarized microscopy. The biopsy taken at 8 weeks post Foundation placement (Fig. 1), shows newly formed woven bone (arrows) and newly formed woven bone with osteoblasts and ongoing bone formation (A). Fig. 2 shows higher magnification of Section A, (from Fig. 1) and also active osteoblasts are observed lining the edge of newly formed woven bone (arrows). Osteocytes are seen embedded in the newly formed woven bone (asterisks). Fig. 3 shows developing blood vessels near the newly formed woven bone (arrow).

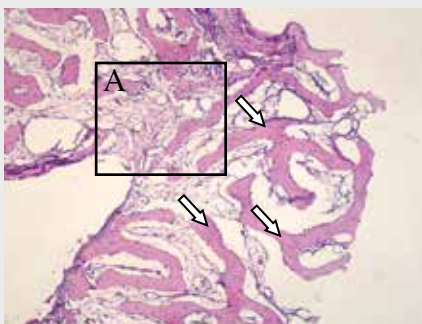


Fig. 1

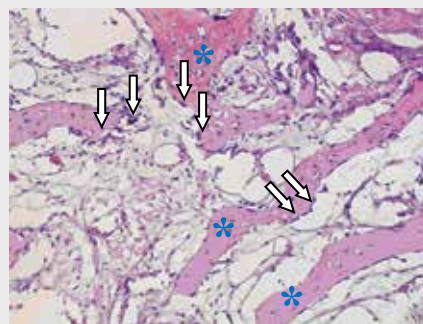


Fig. 2

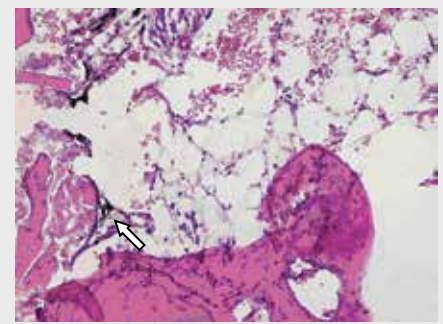
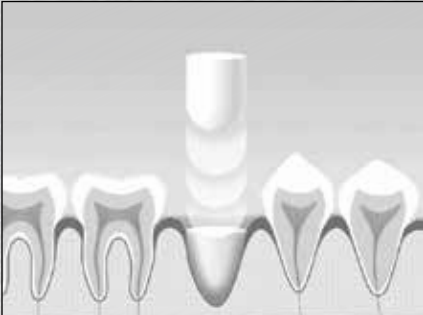


Fig. 3

Stimulates New Bone Growth

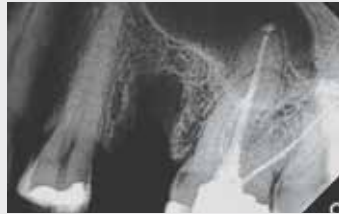

Foundation is a collagen-based, bone filling augmentation material for use after teeth extractions. It is not a bone substitute, but rather stimulates new bone growth. It has been used clinically in Japan since 1998 and has been available in North America since 2006.

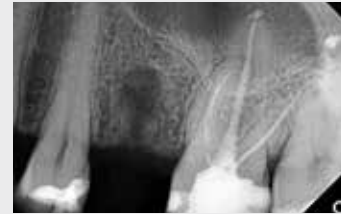Immediately following an extraction, Foundation is placed into the socket. It is shaped in "bullet" form for easy placement and is available in both small and medium sizes. Once inserted, the surrounding cells and capillaries infiltrate Foundation. As the extraction socket heals, it is filled with new augmented bone. There is no need to remove it and no membrane is required.

Foundation is helpful in maintaining bone after any permanent extraction. It is also ideal for pre-implant augmentation, as it will stimulate the bone to fill in allowing implants to be placed sooner, in some cases as early as 8 weeks. It is also recommended for third molar extraction sockets to ensure good "bony" support on the distal of the second molar.

Below is a clinical case demonstrating excellent bone growth in just 8 weeks. Case courtesy of Dr. Arthur J. Greenspoon, La Dentisterie Descelle, Montréal, QC.



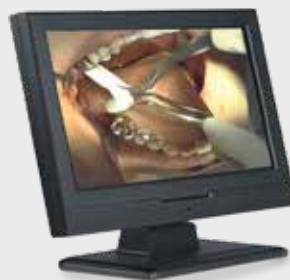Post-extraction



8 weeks post-extraction

Features

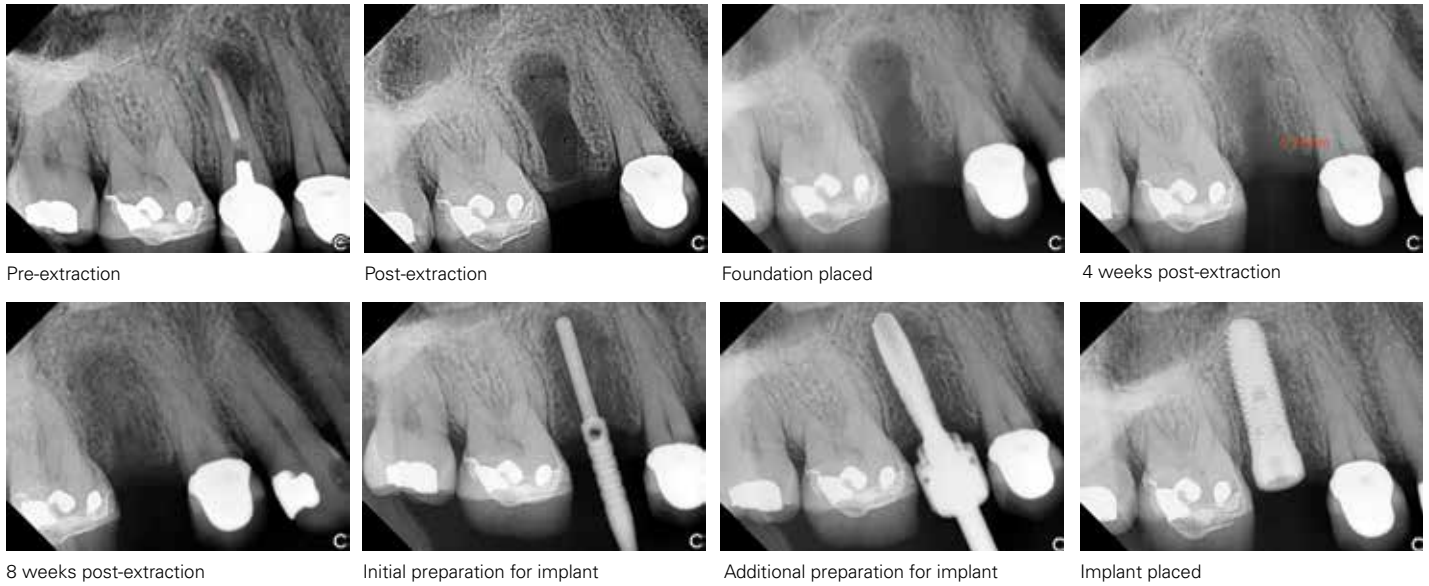
- Collagen-based, bone filling augmentation material
- Promotes bone growth after tooth extraction allowing implants to be placed as early as 8 weeks*
- Helpful in maintaining bone following permanent tooth extraction
- Bullet shaped for easy placement in extraction sockets
- Available in 2 sizes, small and medium
- Can be trimmed or shaped for a better fit
- Independent studies, including University of Rochester, Eastman Institute for Oral Health Research, available upon request



▶ **Demonstration Video & FREE CE Online at:**
www.morita.com/usa/foundation
Click on CE & Awards/Ratings

Examples of Clinical Applications

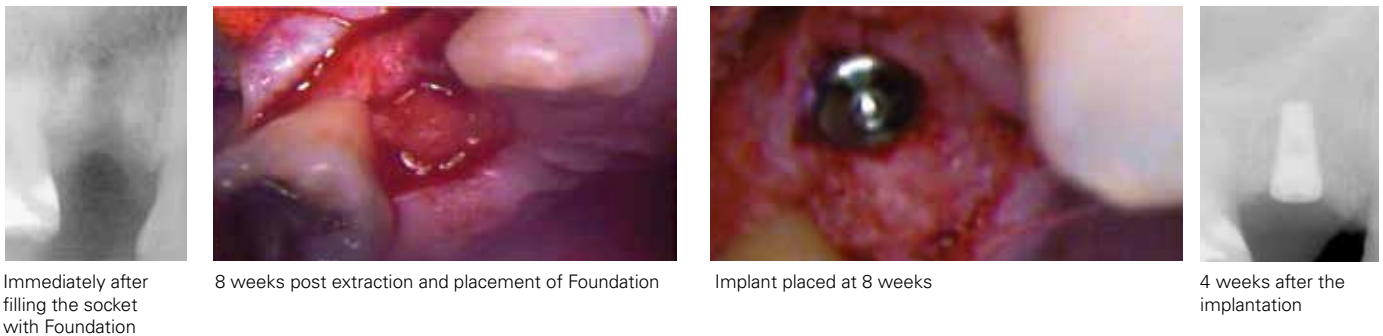
Case 1: 48 year-old female patient. Extraction was performed due to a fracture.



Courtesy: Dr. Arthur J. Greenspoon, La Dentisterie Descelle, Montréal, QC

Case 2: Extraction of a premolar due to fracture in a 31-year-old male

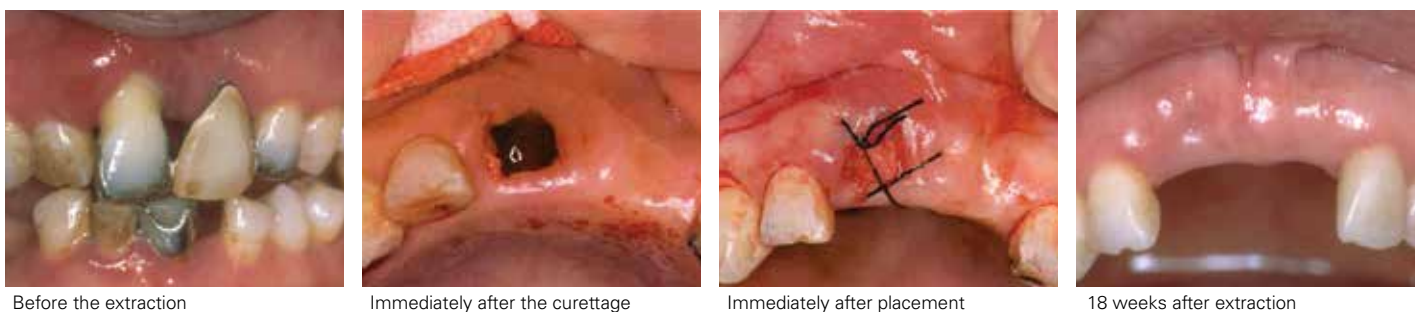
This case shows a single tooth implant that was placed after extraction due to fracture. The root of the premolar was extracted and the socket was filled with an S size Foundation. An x-ray was taken immediately after filling the socket with Foundation. 8 weeks post-op, there is horizontal bone augmentation in the socket. At this point, the bone augmented by Foundation was ready to be prepared and an implant was placed. 4 weeks post-implantation (12 weeks post-Foundation placement), the bone surrounding the abutment was filled in and the implant was firm.



Courtesy: Matsumi Dental Office, Japan

Case 3: Extraction of tooth #8 due to severe periodontal defect in a 65-year-old female

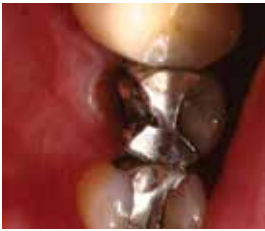This case shows the extraction of tooth #8 due to advanced periodontal disease. #9 is a pontic. The tooth had severe gingival recession and the pus discharge confirmed an infection was present. The extraction was performed after controlling the infection with an antibiotic regimen. After the extraction, unhealthy granulation tissue in the socket was curetted. The resorption of the labial bone reached the root apex. An S size Foundation was used and the gingiva was sutured to secure it. At 18 weeks post-op, it is clearly shown that Foundation augmented the alveolar ridge and created a very good esthetic result.



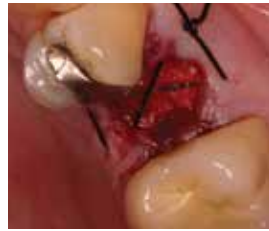Courtesy: Kodama Dental Clinic, Japan

Case 4: Tooth extraction of #13 due to subosseous fracture of the lingual cusp

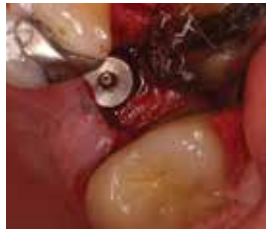Tooth #13 was deemed "hopeless" and was extracted. Foundation was inserted and a passive suture was placed. 8 weeks following extraction, a radiograph confirmed there was sufficient bone to place the implant into a stable base. At 5 months following extraction, the permanent crown was seated.



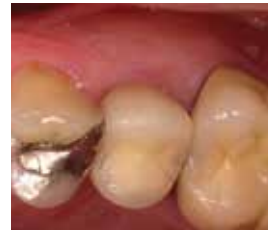Pre-op for tooth #13



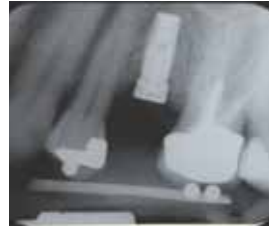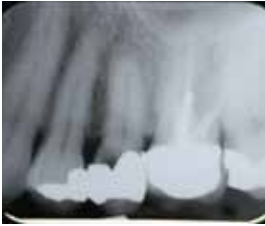Post extraction #13, Foundation placed



8 weeks post extraction #13



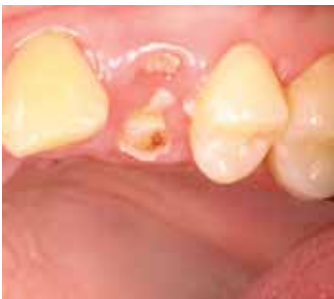5 months post extraction #13



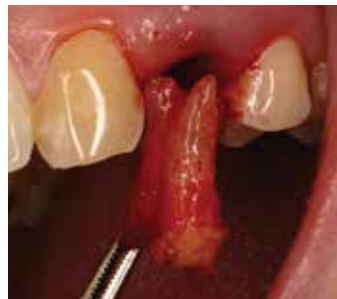Courtesy: University of Rochester, Eastman Institute for Oral Health

Case 5: Extraction of tooth #12 due to gross caries

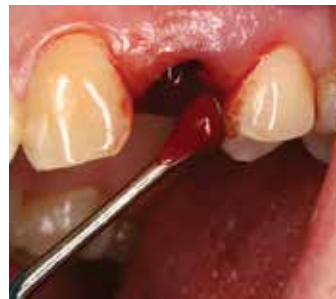The extraction of tooth #12 was necessary due to the extensive decay. The tooth was not restorable. After the root tip was extracted, the socket was thoroughly curetted to expose bone and ensure adequate blood in the socket. Foundation was placed in the socket and the healing process began. At 4 weeks the soft tissue had healed nicely. At 12 weeks an x-ray was taken which revealed adequate bone growth in the socket to place the implant. A panoramic x-ray was taken to demonstrate successful implant placement.



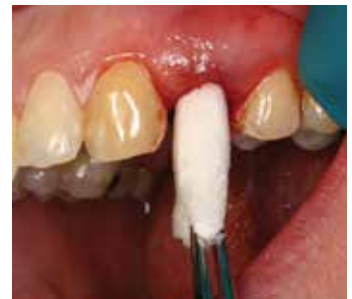Prior to extraction



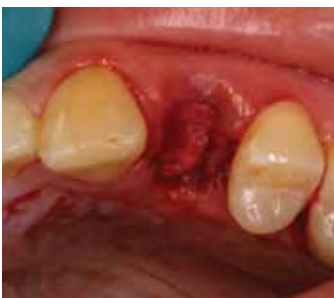Removal of root tip



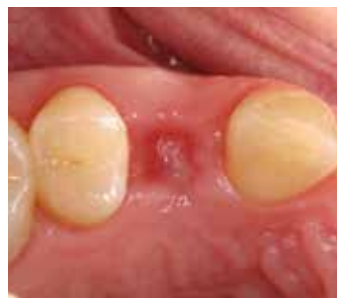Curetting the socket



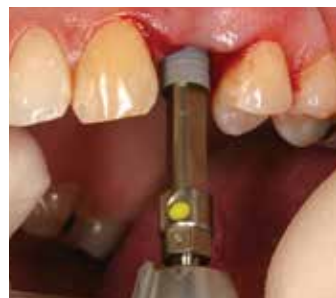Foundation placed into the socket



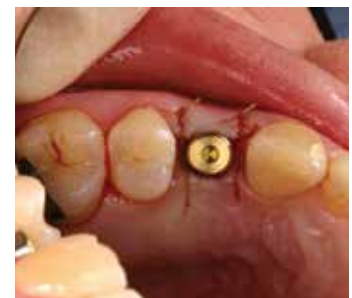Foundation in place



4 weeks post-extraction



Placing the implant



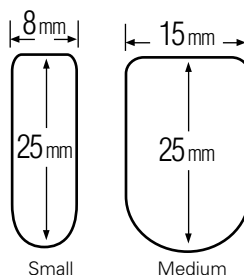
12 weeks - implant placed

Courtesy: Dr. Edward Marcus, Yardley, PA

Ordering Information

All units in each box of Foundation are individually packaged in a sterile container.

- Foundation, size small (10 units) 27-500-100
- Foundation, size medium (5 units) 27-500-200
- Foundation, assortment pack (6 units) 27-500-150
(3 each small & medium)



Small Medium

(Shown actual size)

To order, or for more information, contact your dealer or call 888-JMORITA (566-7482).

Thinking ahead. Focused on life.

In 1916, Junichi Morita started to import products of the leading dental equipment manufacturers into Japan, where demands for modern dentistry were growing. His venturesome attempts of supplying selected products for oral healthcare has grown steadily by receiving valuable support and guidance from the dental profession. His enterprising spirit lives through the decades, and all Morita Group Companies join in continuing to pursue marketing, distribution and services, as well as R&D and manufacturing, in collaboration with world leaders in healthcare products and research organizations.

Diagnostic/Imaging Equipment

Treatment Units

Instruments

Laser Equipment

Laboratory Devices

Educational and Training Systems

Auxiliaries

Distributed by

J. MORITA USA, INC.

9 Mason, Irvine, CA 92618 U.S.A.

Toll Free: (800) 831-3222, Fax: (949) 465-1095, www.morita.com/usa

J. MORITA EUROPE GMBH

Justus-von-Liebig-Strasse 27A, D-63128 Dietzenbach, Germany

Tel: +49-6074-836-0, Fax: +49-6074-836-299, www.morita.com/europe

J. MORITA CORP AUSTRALIA & NEW ZEALAND

247 Coward Street, Suite 2.05, Mascot NSW 2020, Australia

Tel: +61 2 9667 3555, Fax: +61 2 9667 3577, www.morita.com/anz

J. MORITA CORP MIDDLE EAST

Saraya Al Wessam Bldg., Tower A, Appt. 902

Cross roads Tag Roasaa & Abu Heif, Saba Pacha, Alexandria, Egypt

Tel: 203 58 222 94, Fax: 203 58 222 96, www.morita.com/middleeast

J. MORITA CORP.

33-18, 3-Chome, Tarumi-cho Suita City, Osaka, 564-8650 Japan

Tel: +81-6-6380-2525, Fax: +81-6-6380-0585

www.morita.com/asia

J. MORITA MFG. CORP.

680 Higashihama Minami-cho, Fushimi-ku, Kyoto, 612-8533 Japan

Tel: +81-75-611-2141, Fax: +81-75-622-4595, www.morita.com/global